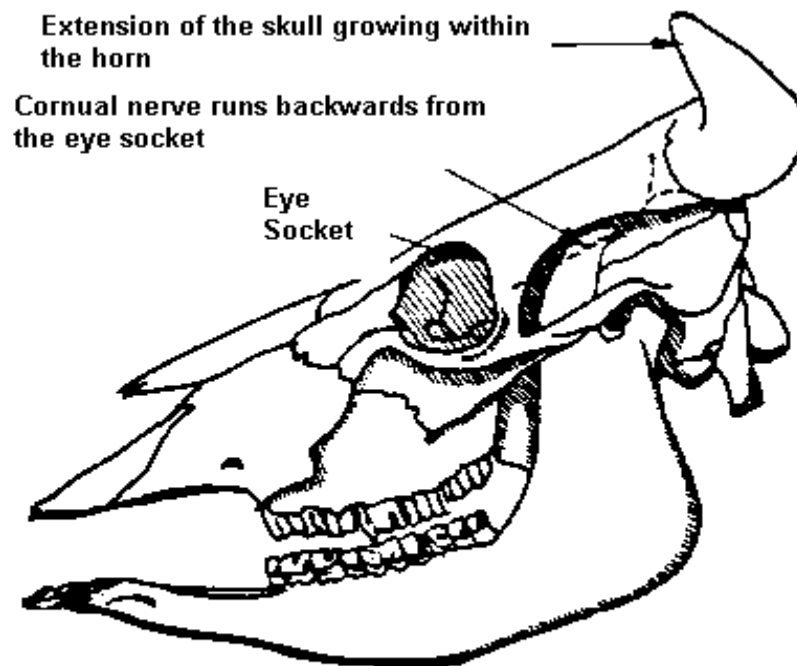


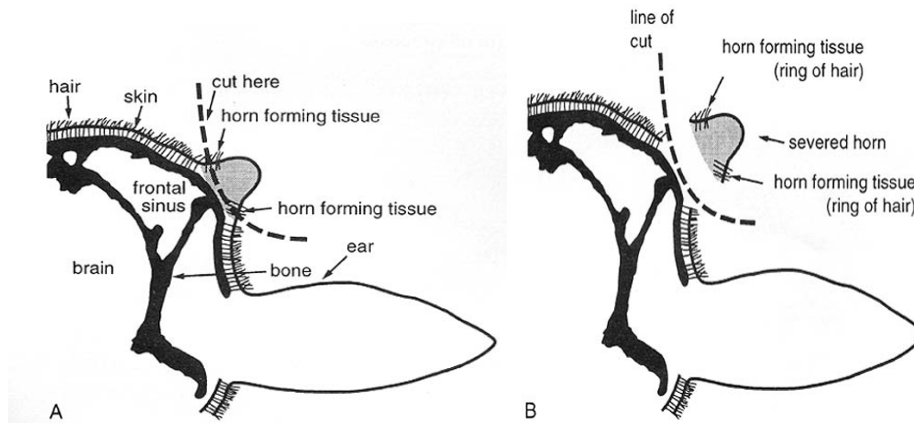
- SOP No:** AHT 57
- SUBJECT:** Surgical Dehorning in Cattle
- POLICY:** This procedure may only be performed by operators skilled in the technique.
This technique is suitable for cattle older than 6 months of age.
- PRECAUTIONS:** The procedure requires accuracy therefore restraining animal movement is critical for the success of the technique. A crush with a headlock offers good restraint that can be further enhanced by the use of a halter and nose pliers. Alternatively, the procedure may be performed using general anaesthesia, for which a crush has been strategically placed to allow release of the patient into a holding pen where the patient is bedded down onto a grass floored area. Aseptic conditions are required throughout the procedure to reduce the risk of bacterial contamination as well as postoperative fly strike
- EQUIPMENT:** Lignocaine 2%
18 Gauge Needles
10m1 Syringes
Isopropyl Alcohol Swabs
Iodine Swabs
Animal Clippers
Standard surgical kit including Vetafil® suture material
Obstetric wire and handle
- PROCEDURE:** 1. **Anaesthesia and Surgical Preparation:** the animal is restrained in a squeeze chute with its head secured to one side with a halter. The hair is removed from the poll, the base of the ears, and the face as far as the eyes. The area is scrubbed and prepared for cornual nerve block, using an 18-gauge, 4 to 5 cm needle. The needle is inserted through the skin at a point midway between the lateral cantus of the eye and the base of the horn. Insert the needle into the upper third of the temporal ridge, immediately behind the ridge and about 2.5 cm below the base of the horn, to a depth of 0.7 to 1.0 cm. At this point 5 ml of local anaesthetic are injected, and another 2 ml are deposited under the skin as the needle is withdrawn. Then the needle is directed subcutaneously toward the base of the horn, and an

additional 2 to 3 ml of local anaesthetic are deposited below the skin. The injection sites are massaged to disperse the local anaesthetic and the procedure is repeated on the other side of the head. Allow 5-10 minutes for the block to be effective.



Surgical technique: an incision is made from the lateral limit of the poll in a lateral direction toward the base of the horn. The incision curves rostroventral around the base of the horn and along the frontal crest for about 5 to 7 cm. A second incision is begun from a point about 5 to 8 cm from the origin of the first incision; this incision is carried around the rostral aspect of the horn, about 1 cm from the base, to unite it with the first incision ventrally. The incisions are deepened until bone is encountered, and the edges of the incisions are undermined using sharp dissection. The stump is then removed using an obstetric wire. The wire must seat itself in the frontal bone at an adequate distance from the base of the horn to allow removal of sufficient bone. The remaining horn is removed following the same technique. The surgical sites are flushed with a suitable physiologic solution, to rinse out any bone

dust. Skin closure is usually performed in one layer using Vetafil® in a simple continuous pattern. Sutures should be removed within 5-10 days.



RECOMMENDATIONS:

Antiseptic, insecticide, and/or insect repellent preparations should be considered as a postoperative measure. Animal should be checked twice daily for 48 hours to detect any signs of sinusitis or skin bacterial contamination or fly strike.

DATE ISSUED: 04.12.2008

REVISED:

REFERENCES

1. Turner A.S. 1989. *Techniques in Large Animal Surgery*. Lea & Febiger. 341 — 344.
2. Dehorning Cattle (1998). NSW Department of Agriculture Publication, SeriesAO 2.4.
<http://www.dpi.nsw.gov.au/agriculture/livestock/beef/husbandry/general/dehorning-cattle>
3. Edwards B. 2001. *Regional anaesthesia techniques in cattle*. In Pract. 23: 142-149